

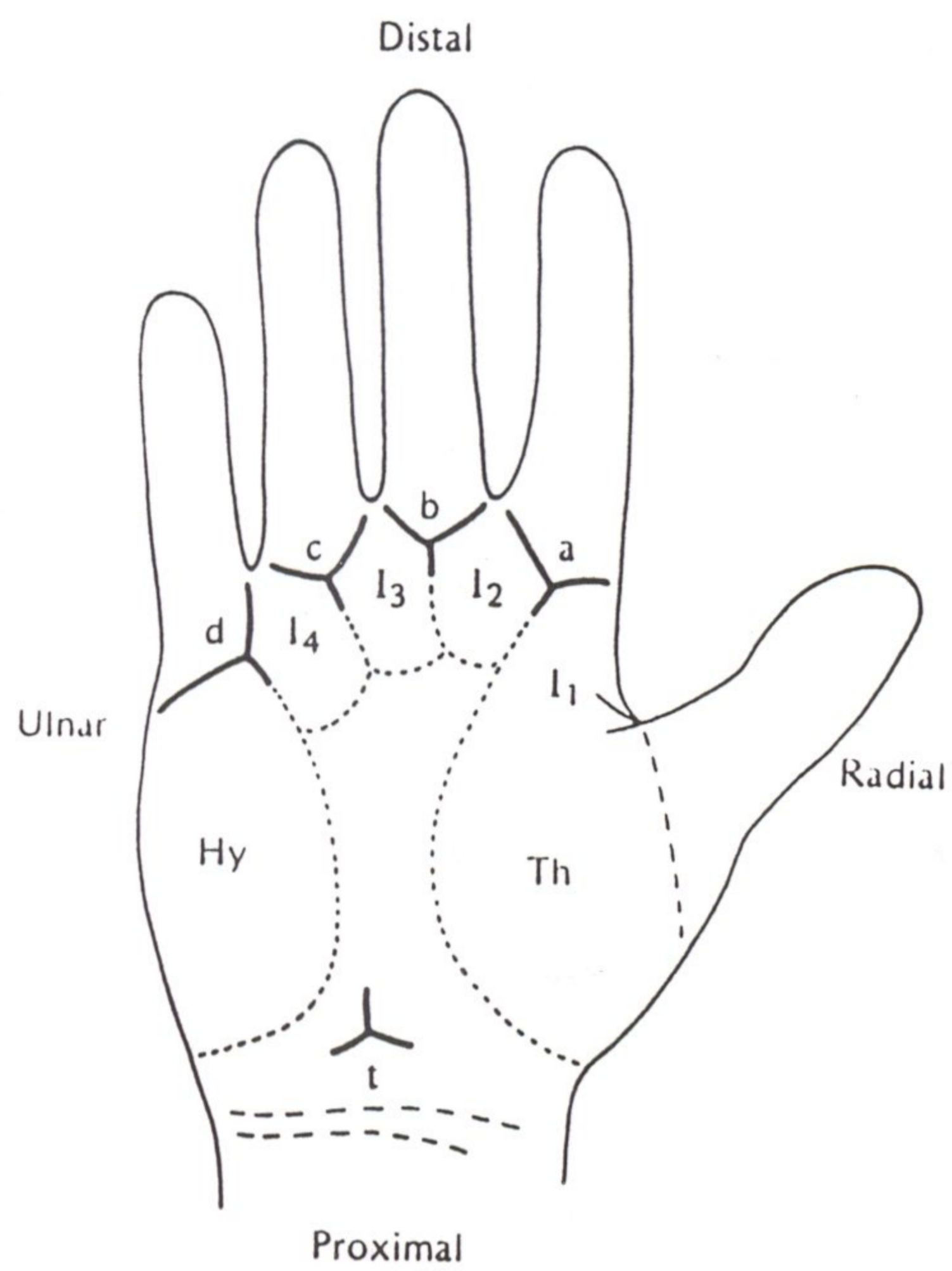FIGURE 3.9 Diagram of a palm showing the dermatoglyphic pattern areas. Th, thenar; Hy, hypothenar; I<sub>1</sub>-I<sub>4</sub>, first-fourth interdigital areas.

A tenyéri párnák

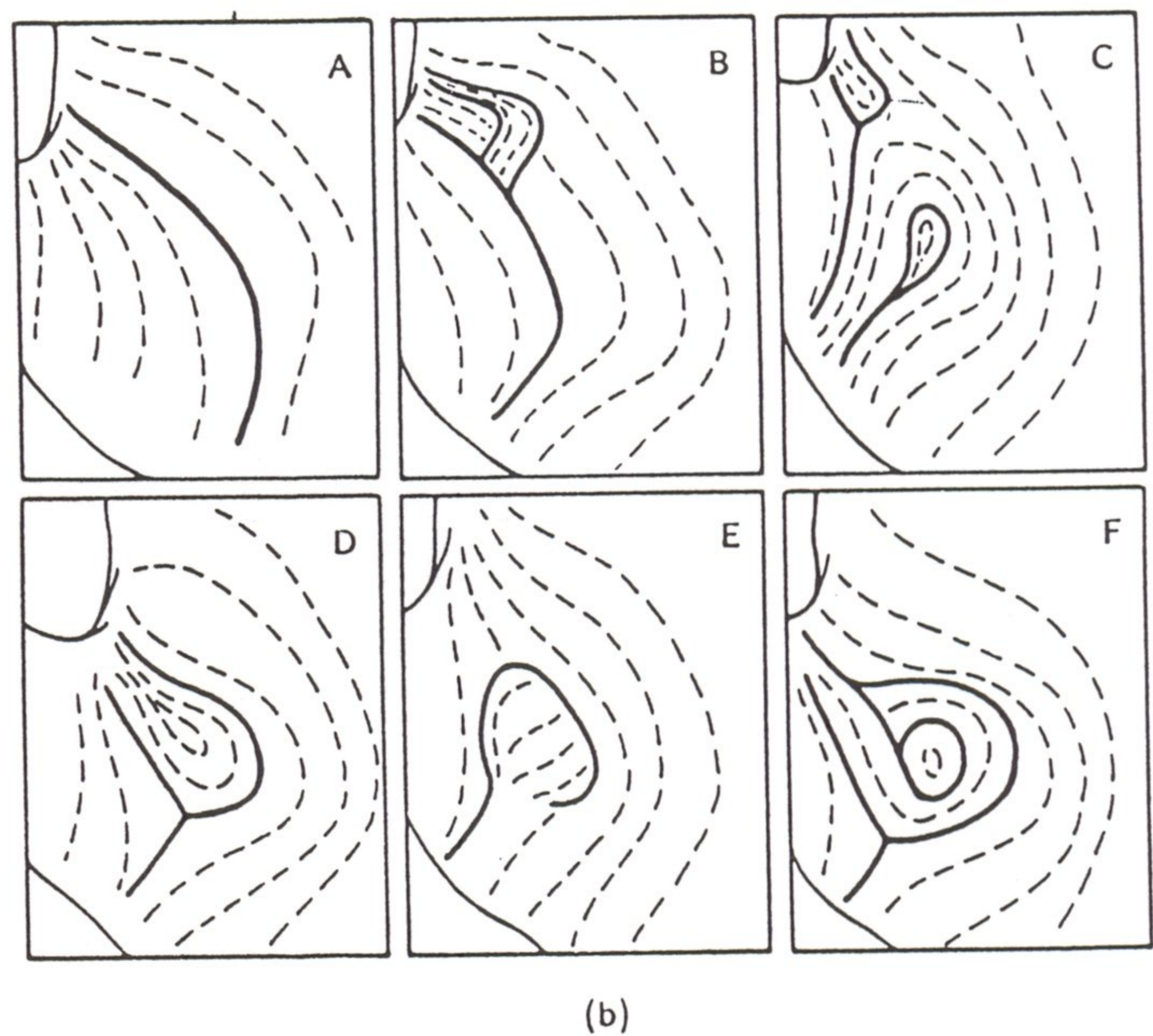
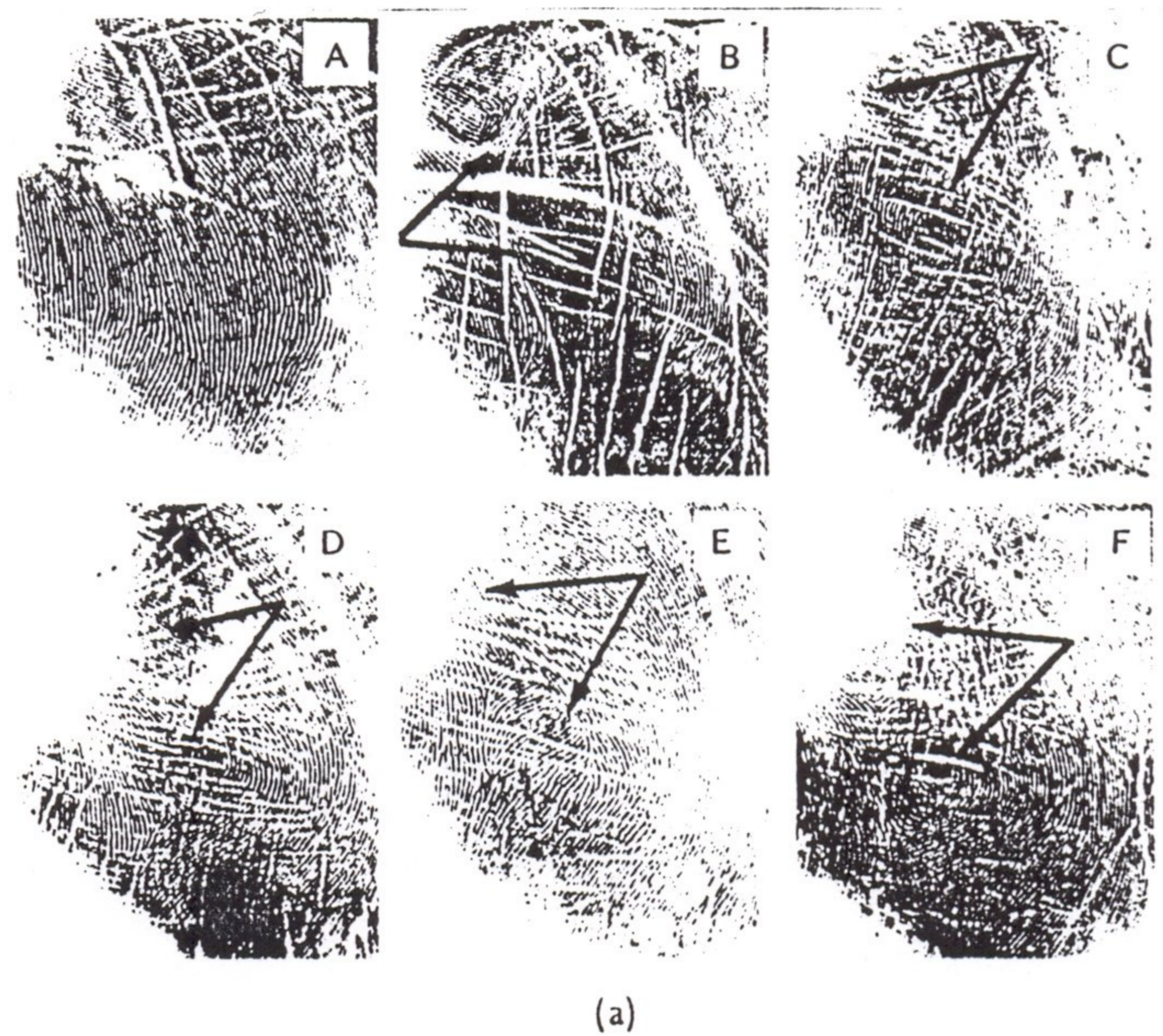


FIGURE 3.11 Types of thenar/first interdigital area patterns: Dermatoglyphic prints (a) and schematic drawings with boldly traced type lines (b). A, open field/open field; B, open field/vestige; C, loop/loop; D, loop/open field; E, vestige/open field; F, whorl/open field.

From Alter, M.: Dermatoglyphic analysis as a diagnostic tool. *Medicine*, 46:35, 1966. Courtesy of The Williams & Wilkins Co., © 1966.

A thenar rajzolatai



FIGURE 3.10 A common type of vestige in the thenar/first interdigital area.

Vestige minta

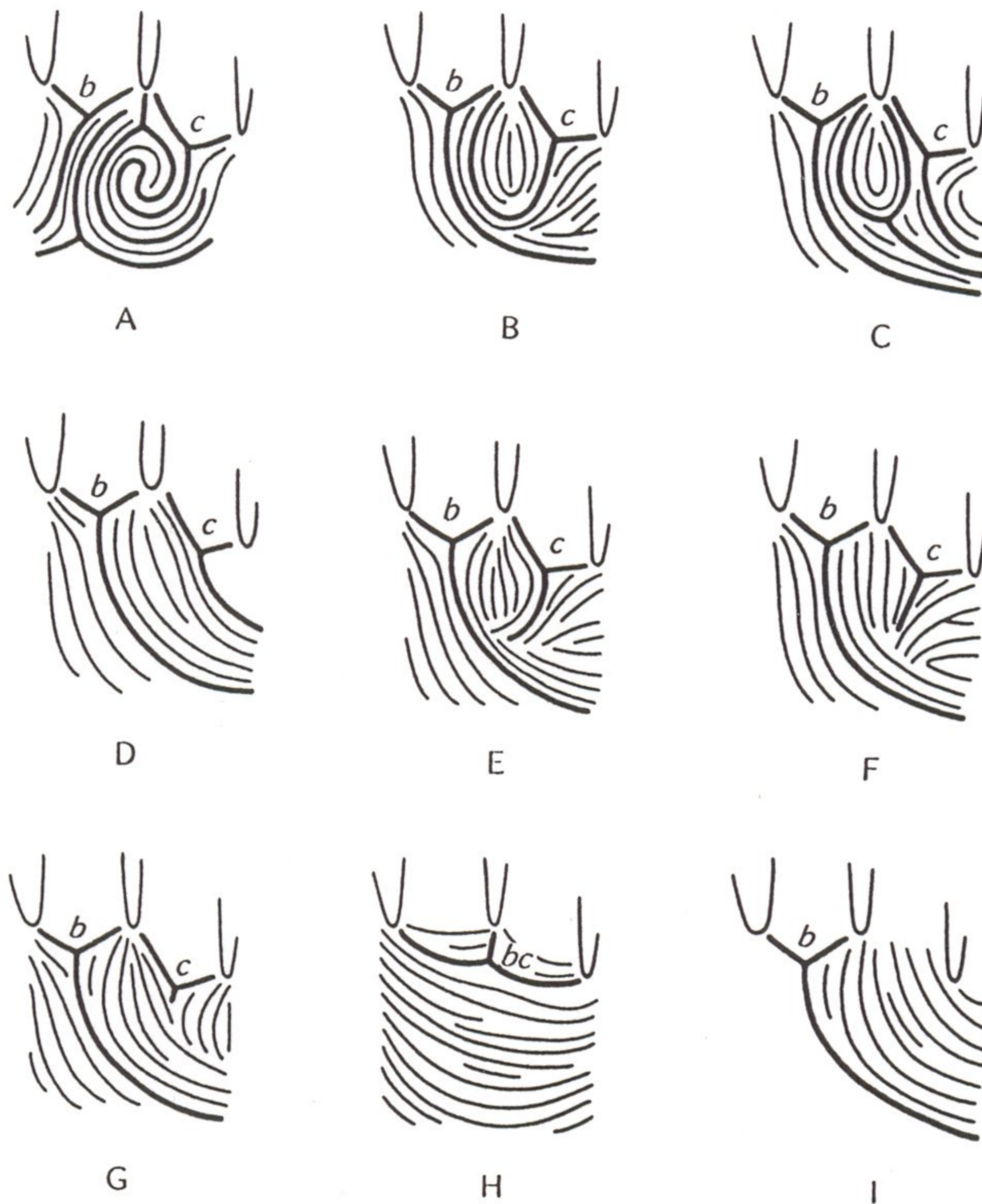


FIGURE 3.12 Diagrams of various ridge arrangements and digital triradii in the interdigital areas. A, whorl; B, loop without an accessory triradius; C, loop with an accessory triradius; D, open field; E, vestige with a tendency toward a loop; F, vestige without a tendency toward a loop, abortive main-line C (symbol X); G, open field, abortive main-line C (symbol x); H, interdigital triradius replacing two usual digital triradii; I, open field, missing digital triradius c.

Interdigitalis rajzolatok

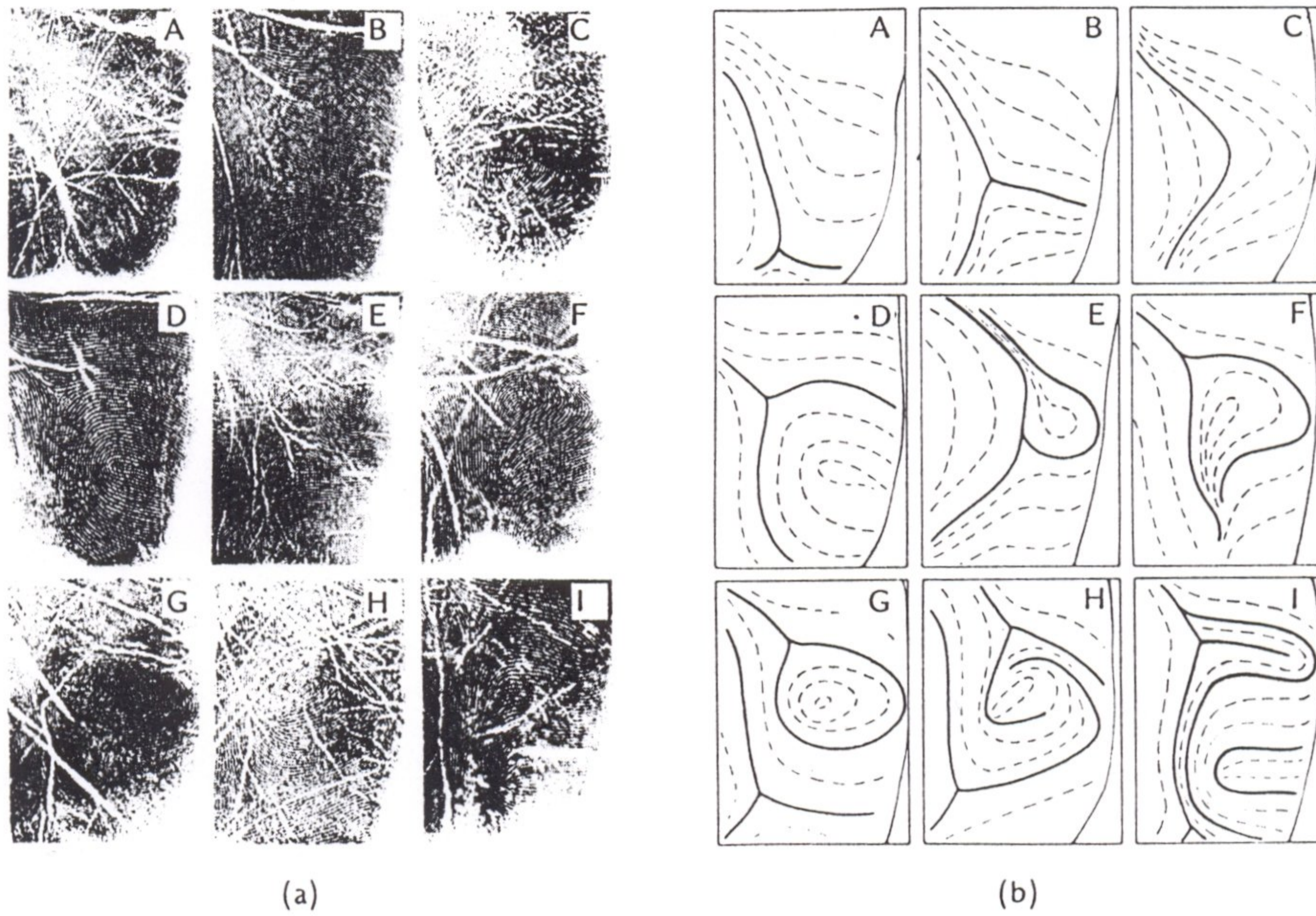


FIGURE 3.13 Some of the types of the hypothenar patterns: Dermatoglyphic prints (a) and schematic drawings (b). A, arch ulnar; B, arch ulnar/arch carpal; C, arch radial; D, loop ulnar; E, loop radial/arch carpal; F, loop carpal; G,H, whorl; I, S-pattern whorl.

From Alter, M.: Dermatoglyphic analysis as a diagnostic tool. *Medicine*, 46:35, 1966. Courtesy of The Williams & Wilkins Co., © 1966.

A hypothenar egyszerű rajzolatai




FIGURE 3.14 Various types of patterns in the hypothenar area. First three vertical columns represent primary types and the four right columns, derived types of patterns. W, whorl; L, loop; T, tented arch; A, simple arch; superscripts r, radial; u, ulnar; c, carpal; d, double loop pattern; s, spiral.

From Penrose, L. S.: Memorandum on dermatoglyphic nomenclature. *Birth Defects*, 4(3):1, 1968. Courtesy of the National Foundation-March of Dimes.

A hypothenar egyszerű és összetett rajzolatai